Online Journal of Health and Allied Sciences
Peer Reviewed, Open Access, Free Online Journal
Published Quarterly : Mangalore, South India : ISSN 0972-5997
Volume 10, Issue 2; April-June 2011

This work is licensed under a
Creative Commons Attribution-
No Derivative Works 2.5 India License

Case Report:

Unusual Large Sporadic Angiomyolipoma Co-existing with Huge Simple Renal Cyst.

Sunil V Jagtap, Department of Pathology,
Dhiraj B Nikumbh, Department of Pathology,
Sushama R Desai, Department of Pathology,
Ashok Y Kshirsagar, Department of Surgery,
Jitendra Khedkar, Department of Pathology,
Swati H Chavan, Department of Physiology,
Krishna Institute of Medical Sciences University, Karad, District Satara, Maharashtra, India - 415110.

Address for Correspondence:
Dr. Dhiraj B Nikumbh,
Assistant Professor,
Department of Pathology,
Krishna Institute of Medical Sciences University,
Karad - 415110,
District Satara,
Maharashtra, India.
E-mail: drdhirajnikumbh@rediffmail.com

Citation: Jagtap SV, Nikumbh DB, Desai SR, Kshirsagar AY, Khedkar J, Chavan SH. Unusual Large Sporadic Angiomyolipoma Co-existing with Huge Simple Renal Cyst. *Online J Health Allied Scs.* 2011;10(2):29
URL: http://www.ojhas.org/issue38/2011-2-29.htm
Open Access Archives: http://cogprints.org/view/subjects/OJHAS.html and http://openmed.nic.in/view/subjects/ojhas.html

Submitted: Jun 4, 2011; Accepted: Jul 20, 2011; Published: Jul 30, 2011

Abstract: Renal Angiomyolipoma (AML) is an unusual benign mesenchymal tumor with no malignant potential. It is composed of adipose tissue, smooth muscle and abnormal thick walled blood vessels. It can occur sporadically or may be associated with tuberous sclerosis. Sporadic angiomyolipoma (AML) coexisting with simple renal cyst is extremely rare and only one case report is available in the literature. In our case, unique combination of sporadic AML along with simple renal cyst with huge size and weight was noted. To the best of our knowledge, ours is the second such case and first case from India. Due to its large size, complete nephrectomy was performed to avoid chances of rupture and retroperitoneal hemorrhage. Post-operative period was uneventful and the patient ahs been on regular follow-up.

Key Words: Renal Angiomyolipoma; Sporadic AML; Simple renal cyst

Introduction:

Renal Angiomyolipoma (AML) is a benign tumor, arises from mesenchymal elements of the kidney.[1] It has an incidence of 0.3 - 3 % and is increased due to advances in imaging modalities.[1] Histologically it is composed of varying proportion of mature adipose tissue, smooth muscle and abnormal thick walled blood vessels. For this reason AML also known as choriostoma in the past.[2] The overall female to male ratio is approximately 4:1, suggesting hormonal component to tumor growth.[3]

It can occur sporadically or may be associated with tuberous sclerosis complex. Isolated AML which occurs sporadically, is often solitary and accounts for 80% of the tumors. The mean age of presentation is 43 years.[4] Interestingly 80% of the cases involve the right kidney. AML associated with tuberous sclerosis accounts for 20% of the tumors; these are larger, often bilateral and multiple. AML occurs in 80% of patients with tuberous sclerosis.[4] In our case angiomyolipoma was sporadic, involved left kidney, large in size and associated with huge simple renal cyst.

To the best our knowledge this is the second such case reported after Csata S et al[5] and first case from India.

Case Report:

A 55 years old woman presented in surgical OPD in our hospital with huge lump in the abdomen, associated with history of recurrent pain in the abdomen, anorexia, dyspnoea and weakness since one year. There was no history of gross hematuria. She had no personal or family history of tuberous sclerosis complex.

Routine investigations revealed - Hb 6.7 gms%, TLC - 4100/cumm, polymorphs 82%, lymphocytes 18%; urine examination showed albumin traces, WBCs 4-5/HPF; BUN - 48 mg %, Serum creatinine 1.7 mg%. ECG was within normal limits. Ultrasonogaphy revealed internal echoes and a huge cystic mass measuring 26 x 25 cms, appearing to be arising from the pelvis of left kidney or ovary. Right kidney showed mild hydronephrosis. Uterus and ovaries were not seen separately. Rest of the organs were normal. In view of the large size and risk of retroperitoneal hemorrhage, exploratory laparotomy - left nephrectomy with excision of the mass was done. The post operative was uneventful and patient has been on regular follow up.

Pathological Findings:

Grossly, the mass with left kidney and ureter, measured 30 x 30 x 27 cms and weighed 7.1 kgs. External surface showed multiple bosselations with a solid area near hilum. Cut surface showed large unilocular cyst measuring 26 x 25 x 25 cms with inner smooth surface and contained clear to yellowish fluid (Figure 1a,1b and 1c). Solid area near hilum measured 9 x 8 x 5 cms and cut section of which was uniform, solid, gray white to tan yellow. Cystic or other degenerative changes were absent in solid mass. Compressed atrophic renal tissue was seen near the hilum.

Figure 1a, 1b and 1c (top to bottom): Gross photographs of cut surface of huge renal cyst with pale yellow to gray white tumor (angiomyolipoma).

On light microscopy, multiple sections from the cyst showed thickened fibrous wall lined by single layered cuboidal to flat epithelium (Figure 2). Multiple sections from solid area near hilum revealed a tumor composed of mature adipose tissue, smooth muscle and tortuous thick walled blood vessels (Figure 3 and 4). Smooth muscle component was predominantly arranged in sheets and fascicles having blunt ended nuclei and moderate amount of eosinophilic cytoplasm. There was no evidence of cystic change within the tumor proper. The adjacent renal parenchyma showed atrophic change.

Final histopathological diagnosis was given as Sporadic Renal Angiomyolipoma with Huge Simple Renal Cyst.

Discussion:

The renal AML has an incidence of 0.3 to 3% of all kidney tumors.[1] The tumors may remain silent for many years or are discovered on imaging studies. It may also present with flank or abdominal pain in 50% of patients or hematuria in 20% of patients.[6] The most important association of this tumor is with tuberous sclerosis. In this setting, 71% are bilateral and 87% are multiple. The mean age of diagnosis is 41 years with female preponderance.[7] The mean size of the AML is reported as 1 cm in those with tuberous sclerosis. The average size of AML is 9 cm but varies from 3-20 cm.[6]

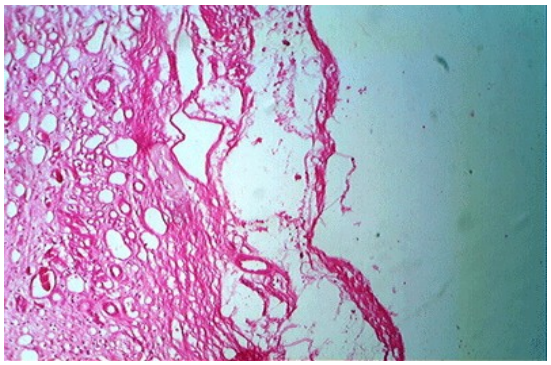

Figure 2: Photomicrograph of simple renal cyst lined by flattened epithelium with surrounding atrophic renal tissue (H and E 40X).

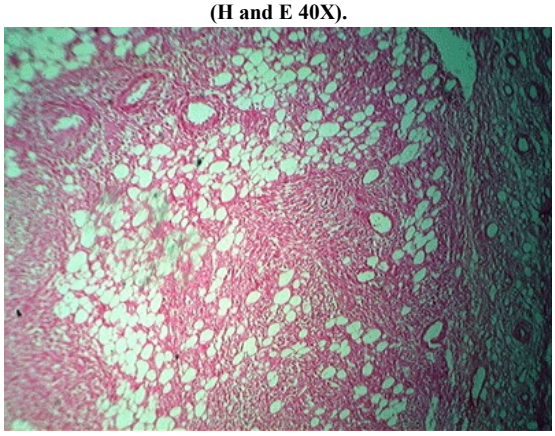

Figure 3: Photomicrograph of triphasic component of angiomyolipoma with compressed normal renal parenchyma (H and E 10X).

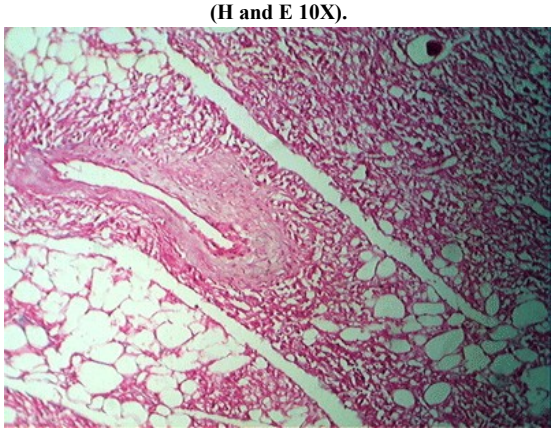

Figure 4: Photomicrograph of angiomyolipoma comprising admixture of adipose tissue, smooth muscle and thick walled blood vessels (H and E 40X)

The combination of renal cysts with tumors is infrequent and varies from 2.1 to 3.5% in various series.[7] The association of sporadic AML and simple renal cyst is extremely rare and only one case report is available in literature from Hungary in 1996.[5]

The sporadic AML occurs at an average age of 45 years and the average size is 9 cms with female preponderance with ratio is 4:1.[8] Right kidney is affected in 80% cases. The tumor is incidental diagnosis on imaging or presents as retroperitoneal hemorrhage.

Our patient presented with sporadic AML coexisting with huge simple renal cyst, an extremely rare clinical entity with left kidney involvement. The patient was 55 years female with no fam-

ily or personal history of tuberous sclerosis (multisystem syndrome characterized by neurological symptoms and tumors in multiple organs including kidney, brain, skin ,eyes, heart and lung).[2]

In view of the large size of tumor with huge simple renal cyst, our patient was subjected to laparotomy and excision of mass to avoid rupture of cyst and retroperitoneal hemorrhage.

Incidence of simple renal cyst is up to 20% in individuals above 55 years, usually as an incidental finding with no symptoms. Occasionally the larger cysts may be palpable and symptoms can arise from rupture, hemorrhage, infection and internal obstruction. Rarely they cause compression of adjacent vessels causing renal ischemia and hypertension.[6] The mean largest cyst diameter was 20.89 + 12.62 mm (range 4-71 mm) as per Chang et al.[9]

In our case, the cyst was single, huge and symptomatic (that was abdominal pain, obstruction and hydronephrosis of right kidney). Usually cyst gets ruptured due to its size, however in our case, the cyst was intact, there was no evidence of rupture or hemoperitoneum. The cyst measured 26 x 25 x 25 cms, and the cyst was separate from AML by atrophic renal parenchyma. To the best of our knowledge, this is the second such case after Csata S et al.[5]

Simple cysts are usually unilocular and filled with clear yellowish fluid and lined by single cuboidal to flattened epithelium. These features were same in our case. Such type of cysts usually don't require treatment. If the treatment is required in view of complication, simple excision of cyst, needle cyst puncture with or without sclerosing agents (lipodiol, alcohol, phenol), percutaneous or laparoscopic unroofing or partial nephrectomy can be done.[9] Our patient underwent complete nephrectomy due to its large size and risk of complication as rupture and retroperitoneal hemorrhage.

Angiomyolipoma (AML) may be confused with other mesenchymal tumors of the kidney. They are leiomyoma, leiomyosarcoma, liposarcoma and sarcomatoid renal cell carcinoma (RCC). This is particularly problematic when predominant smooth muscle component is associated with nuclear atypia and necrosis. The presence of triphasic components like adipose tissue, smooth muscle, and characteristic thick walled blood vessels differentiate it from leiomyoma. Similarly these features, with paucity of mitotic figures and necrosis, separate AML from leiomyosarcoma. Lipoblast and characteristic chicken wire configuration of vessels are the hallmark of liposarcoma, which are not seen in AML. Sarcomatoid RCC contains biphasic components as interlacing bundles and fascicles of spindle cells with clear cell, chromophobe or papillary carcinomatous elements. Presence of separate huge cyst on gross and microscopic separation between AML (without cystic change) and simple cyst by epithelium and compressed atrophic renal tissue in between both differentiate it from cystic variant of AML.[2]

Differential diagnosis of simple renal cyst is multilocular renal cell carcinoma (MCRCC). MCRCC is characterized by multiple cystic spaces separated by thick fibrous septa, containing aggregates of clear cells, whereas simple cyst is lined by simple flat to cuboidal epithelium.

To conclude, association of sporadic AML with simple renal cyst is extremely rare, only one case report is available in the literature. To the best our knowledge, we report second case of large sporadic AML coexisting with huge simple renal cyst. In our case in spite of huge size of simple renal cyst, there was no evidence of rupture or retroperitoneal haemorrhage.

References:

1. Steiner MS, Goldman SM, Fishman EK, Marshall FF. The natural history of renal angiomyolipoma. *J Urol* 1993,150:1782-86.
2. Murphy WM, Grignon DJ, Perlman EJ. Kidney tumors in adults. In Murphy WM, Grignon DJ, Perlman EJ (editor). Tumors of the Kidney, Bladder and Related Urinary Structures. AFIP. Fourth series, Fascicle 1. Washington DC, 2004.
3. Nelson CP, Sanda MG. Contemporary diagnosis and management of renal angiomyolipoma. *J Urol* 2002;168(1):20-24.
4. Angiomyolipoma- Kidney. [Internet] 2011. cited on 2011 March 1. Available from http://www.thedoctorsdoctor.-com/diseases/kidney_angiomyolipoma.htm
5. Csata S, Repassy D, Domotor L. Co-incidence of angioleiomyolipoma and renal cyst. A*cta Chir Hung.*1995-96;35(3-4):355-359.
6. Jimenez RE et al. Concurrent Angiomyolipoma and Renal cell neoplasia: A study of 36 cases. *Mod Pathol* 2001;14:157-63.
7. Hill GS. Cystic and dysplastic disease of the kidney. In Hills GS (editor). Acquired lesions in Uropathology. Churchill Livingstone, 1st ed. 1989(1);173-88.
8. Milan JC. Tumors of the kidney. In: Hills GS (editor). Acquired lesions in Uropathology. Churchill Livingstone, 1st ed. 1989(1); 623-701.
9. Chang CC, Kuo JY, Chan WL, Chen KK, Chang LS. Prevalence and Clinical Characteristics of Simple Renal Cyst. *J Chin Med Assoc.* 2007;70(11):486-491.